

Lung Cancer Screening Test Form

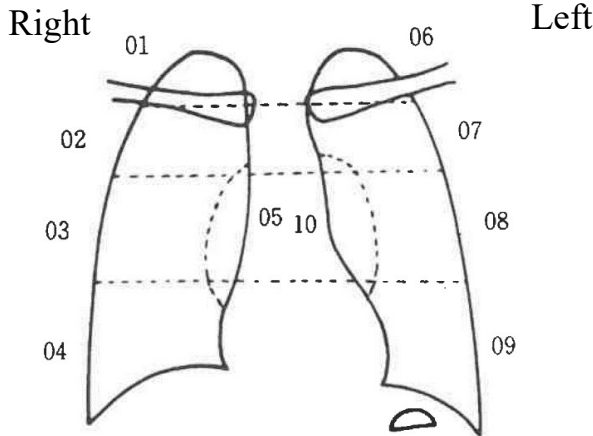
City/Town/Village		Film No.		Date of examination		Month/Day/Year	
kana				Address			
Name							
Date of birth		Sex		Age at the year-end	As of March 31, 2023 years old	Terephone number	*Daytime phone number

***Please fill out the space within the thick lines by yourself.**

<p>[1] Have you had lung cancer screening in the past? What was the result?</p>	<p>1. Had in the last year 2. Had 2 years ago 3. Had 3 years ago 4. No or had before "3 years ago" 9. I do not know</p> <p>1 No abnormality 2. Abnormal</p>
<p>[2] Have you ever had lung diseases? If yes: What is the name of the disease?</p>	<p>1. No 2. Yes, around the age of () years</p> <p>Pulmonary tuberculosis / pleurisy / bronchitis / pneumoconiosis/ other ()</p>
<p>[3] Do you have any symptom related to lung diseases at present?</p> <p>[4] Do you recently have cough?</p> <p>[5] Do you recently have sputum?</p> <p>[6] Have you had bloody sputum within last 6 months?</p>	<p>1. No 2. Yes 9. I do not know</p> <p>1. No 2. Sometimes 3. Everyday</p> <p>1. No 2. Sometimes 3. Everyday</p> <p>1. No 2. Yes</p>
<p>[7] Do you smoke?</p>	<p>1. No</p> <p>2. Yes (cigarettes/day × years)</p> <p>3. Previously smoked (cigarettes/day × years)</p>
<p>[8] Have you been engaged in operations involving the followings?</p>	<p>1. Yes 2. No</p>
<p>1. Radiation 2. Mine (coal/metal) 3. Asbestos 4. Hexavalent chromium 5. Coal tar 6. Painting 7. Other</p>	<p>Number of years of engagement () years</p>

Sputum	Yes / No
--------	----------

Smoking index	cigarettes
---------------	------------



First interpretation	Region	Findings	Determination
1			
2			
3			

Second interpretation	Region	Findings	Determination
1			
2			
3			

Overall determination	
------------------------------	--

Determination	X-ray findings	Details
A	Not interpretable	Unreadable due to poor imaging conditions, poor image development processing, poor positioning, scratch on the film, and artifact
B	No abnormal finding	Including normal subtype (pericardial fat pad, tent-shape/arch-like deformation of diaphragm, accompanying shadow due to subpleural adipose tissue, double shadow at the right heart border)
C	Abnormal findings not requiring detailed examination	Shadows including old lesion, calcified shadow, fibrous changes, bronchodilator image, emphysematous changes, postoperative changes, deformation not requiring treatment considered unlikely to require detailed examination or treatment or urgent examination or treatment
D1	Active pulmonary tuberculosis	Suspected with tuberculosis requiring treatment
D2	Active non-tuberculous lesion	Suspected with conditions requiring treatment such as pneumonia, pneumothorax
D3	Cardiovascular disease	Suspected with conditions requiring treatment for major cardiovascular abnormality such as aortic aneurysm
D4	Other	Suspected with condition requiring treatment such as mediastinal tumor, chest wall tumor, and pleural tumor, etc.
E1	Likelihood of lung cancer cannot be ruled out	
E2	Strongly suspected with lung cancer	Isolated shadow, development of new shadows in old lesion, abnormality in the hilar region (tumor shadow, deviation of hilar structures such as blood vessels/bronchus), secondary changes due to bronchial stenosis/obstruction (segmental/lobe/lobar pneumonia/atelectasis/emphysema) and other findings suggestive of lung cancer